AWARENESS ON PROSTHODONTIC TREATMENT PLANNING IN PATIENTS UNDERGOING RADIATION THERAPY

[1]Bharathi.S, [2]Dr. Dhanraj

[1]Student (CRI), [2]Professor Doctor (Department of Prosthodontics)
SAVEETHA INSTITUTE OF MEDICAL AND TECHNICAL SCIENCES, CHENNAI, INDIA

ABSTRACT:

Aim: The main aim of the article is to know about the awareness on prosthodontic treatment planning in patients undergoing radiation therapy.

Background:
Radiation therapy is the most common form of treatment along with surgery and chemotherapy for cancer patients . One of the most common cancer is head and neck cancer. Prosthodontist is involved in the diagnosis, examination, treatment, maintenance of oral function, speech, cosmetics, and health of patients undergoing cancer treatment.Various prosthodontic management methods are used in these patients.

Materials and methods:
A cross sectional survey was initiated from a randomly chosen population of 100 undergraduate dental students. The survey was conducted online using survey planet online survey tool. The survey instrument used was a pretested questionnaire comprising of 11 questions eliciting responses pertaining to the awareness among dental practitioners on prosthodontic treatment planning in patients under radiation therapy.

Result:
Overall, awareness about prosthodontic treatment planning in patients undergoing radiation therapy is poor among dental students.
Conclusion:
Therefore, communication and education should be improved for dental students about prosthodontic treatment planning on patients undergoing radiation therapy through various educational programmes, workshops and conferences.
This is because patient's oral function and aesthetics are the prime factor in patients undergoing radiation therapy.

INTRODUCTION:
Quality of life of patients suffering with cancer is highly compromised due the disease itself, post-surgical disability or limitation, ill effects of radiation, and side effects of chemotherapeutic drugs. One of the most common cancer by incidence and one of the common cause of death from cancer worldwide is Head and neck cancer. Head and neck cancers (HNC) are often treated with radiation therapy (RT), a technique that utilise ionising radiation and exerts therapeutic effect by semi-selectively damaging the genetic material of malignant cells, either directly or through the production of free radicals, resulting in cell death. Radiotherapy (RT) is used to treat intra-oral cancers as a primary treatment modality or as an adjuvant treatment pre or post-surgery [1,2]

Patients with head, neck cancer suffer from jaw deviations due to mandibulectomy and maxillectomy in various forms like from total to segmental which ultimately impairs masticatory function, speech, xerostomia due to radiation, nasal reflux due to oronasal fistula, cosmetic disfigurement, and radiation caries. The oral complications of head and neck RT results radiation injury to the salivary glands, oral mucosa and taste buds, oral musculature, alveolar bone, and skin. They are clinically manifested by xerostomia, oral mucositis, dental caries, accelerated periodontal disease, taste loss, oral infection, trismus, and radiation dermatitis [3]. Patients often require rehabilitation for swallowing, mastication, speech, cosmetics to lead happy social life. Prosthodontic rehabilitation requires coordinated integration with a multidisciplinary team. (fig 1)

FIGURE-1

Members of this team include a surgical oncologist, radiation oncologist, prosthodontist, oral maxillofacial surgeon, speech therapist, otolaryngologist, and social worker to treat and make patients comfortable.[4] An important and critical member of this team is prosthodontist who coordinates with team members in every stage of patients treatment. Prosthodontist is involved in the diagnosis, examination, treatment, maintenance of oral function, speech, cosmetics, and health of patients undergoing cancer treatment.[5] Dental management should begin pre treatment and continue during and after treatment. So , the aim of this research is to know about the awareness among dental students about dental management (pre treatment , during treatment and post treatment) in patient undergoing radiation therapy.

FIGURE-2

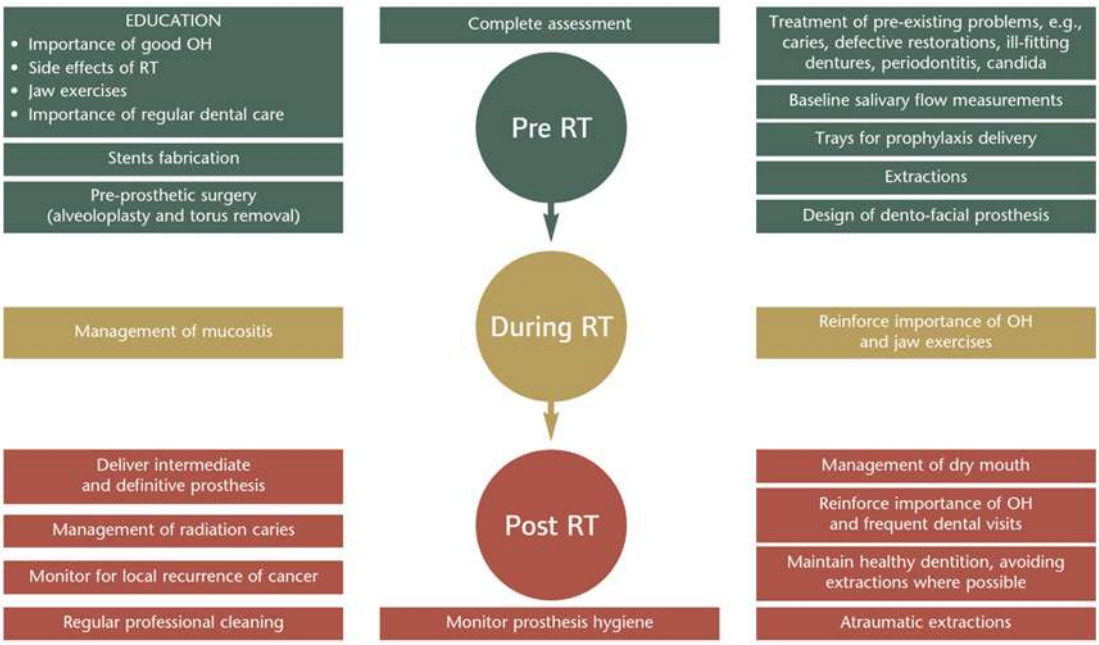

PRE TREATMENT:

To gather baseline information on the oral health status of patients at the moment of their first consultation, i.e., before RT, the following data should be collected from the patient's chart: age, gender, ethnicity, tumor site, tumor staging, tumor histology, presence of unrecoverable teeth, presence of residual roots, presence of unerupted teeth, use of dentures, periodontal alterations (crestal bone loss relative to the distance from the apex to a point 2 mm apical to the cemento-enamel junction, determined by radiographic examination), caries, candidiasis (defined as the clinical presence of removable white intraoral plaques or white lesions associated with erythematous lesions), and xerostomia (assessed in a "yes/no" manner). Upon the first visit, patients should be interviewed, clinically examined, and a complete set of oral radiographs should be taken, patients should be educated about oral care instructions by dental hygienists, whereas those who did not have teeth should be instructed on how to clean their mouth with gauze soaked in 0.9% NaCl solution, patients who wore prostheses should be advised to place them overnight in a glass of water, extractions and periodontal surgical procedures should be performed before RT, whenever a minimum interval of 15 days could be respected before initiation of RT, patients should be prescribed sucralfate mouthwash at 10% (four times a day/duration of 10 min; used concomitant with irradiation), and sodium fluoride at 1% was prescribed to dentate patients (nightly mouthwash/duration of 1 min; used concomitant with irradiation), patients should undergo weekly oral examinations and prophylaxis during RT.

DURING TREATMENT:
In this stage, Nontraumatic therapy, such as restorative dentistry and endodontics, was performed during RT. The information on mucositis, candidiasis, and xerostomia should be gathered from the patients' charts.

AFTER RADIOTHERAPY:
Patients continued to be followed up after the end of RT, with the minimum post-RT period for inclusion into this stage of the study being 3 months. The frequency of followup visits after RT varied from patient to patient, according to oral health status upon completion of RT. Mucositis, candidiasis, xerostomia, radiation caries, and osteoradionecrosis information should be gathered from the charts. Prosthodontic therapy was postponed until the end of RT. [6,7].

MATERIALS AND METHODS:
A cross sectional survey was initiated from a randomly chosen population of 100 undergraduate dental students. A simple random sampling technique was used to identify the samples. Inform consent was obtained from the participants and confidentiality of the records were ensured. The survey was conducted online using survey planet online survey tool. The survey instrument used was a pretested questionnaire comprising of 9 questions eliciting responses pertaining to the awareness among dental practitioners on prosthodontic treatment planning in patients under radiation therapy. The students were asked to fill the survey and results were calculated.

Questionnaire:
1. Are you aware that prosthodontic rehabilitation is unfavourable and challengeable in patients taking radiation therapy?
2. Are you aware about the effect of radiation therapy in teeth?
3. Are you aware about the prosthodontic management of patients undergoing radiation treatment?
4. Are you aware about the precautions to be taken during placement of implant on patients undergoing radiation therapy?
5. Are you aware about the use of tissue conditioners and soft liners in the prosthodontic management of patients undergoing radiation therapy?
6. Are you aware about sialogogues or any artificial saliva inducing agents used in the management of patients undergoing radiation therapy?
7. Are you aware of specific oral hygiene measures in patients undergoing radiation therapy?
8. Are you aware about denture hygiene in these kind of patients?
9. Are you aware about the advances in the prosthodontic management of patients undergoing radiation therapy?

RESULTS:
The results were calculated using a online survey tool and was presented in a form of pie chart for each question. When it comes to Overall result, the awareness was less about prosthodontic treatment planning in patients undergoing radiation therapy among dental students.

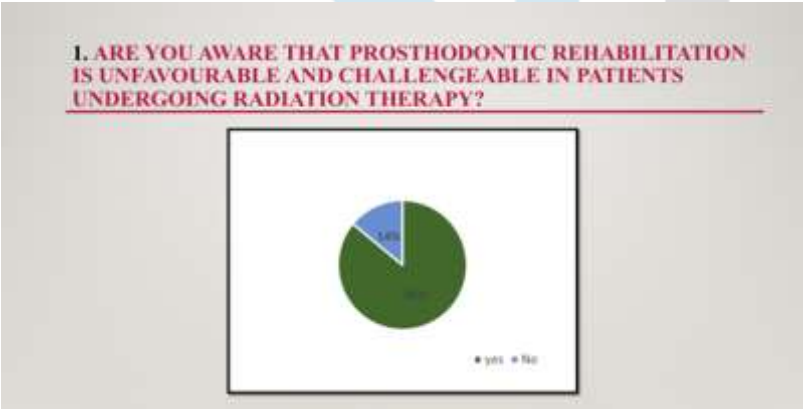

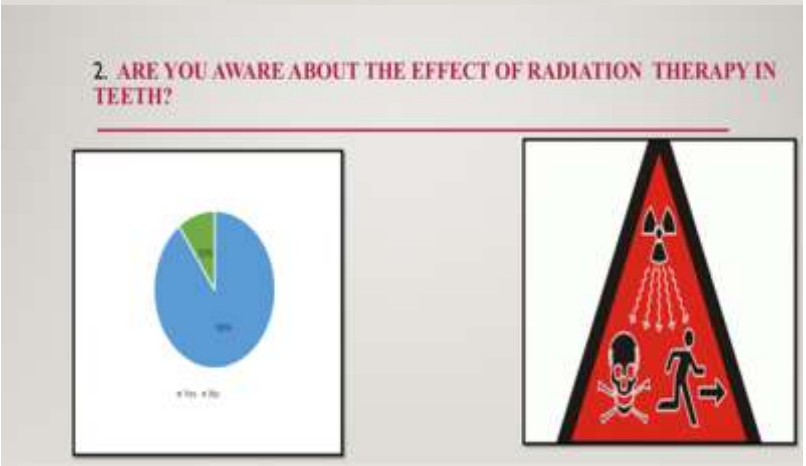

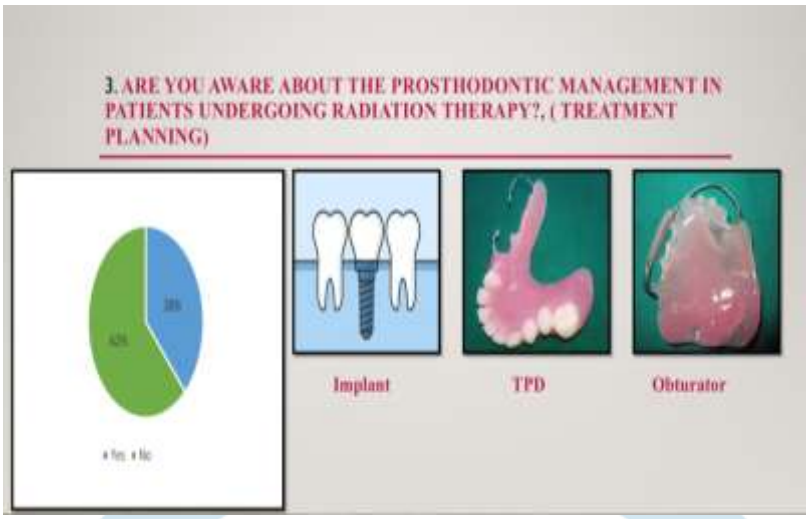
3. ARE YOU AWARE ABOUT THE PROSTHODONTIC MANAGEMENT IN PATIENTS UNDERGOING RADIATION THERAPY?, (TREATMENT PLANNING)
Implant
TPD
Obturator

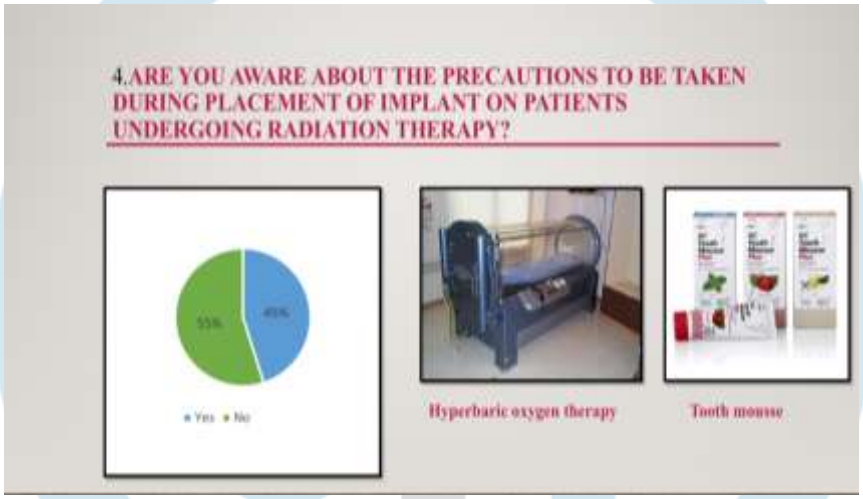
4.ARE YOU AWARE ABOUT THE PRECAUTIONS TO BE TAKEN DURING PLACEMENT OF IMPLANT ON PATIENTS UNDERGOING RADIATION THERAPY?
Yes
No
Hyperbaric oxygen therapy
Tooth mousse


5.ARE YOU AWARE ABOUT THE USE OF TISSUE CONDITIONERS AND SOFT LINERS IN THE PROSTHODONTIC MANAGEMENT OF PATIENTS UNDERGOING RADIATION THERAPY?
62%
Yes
No

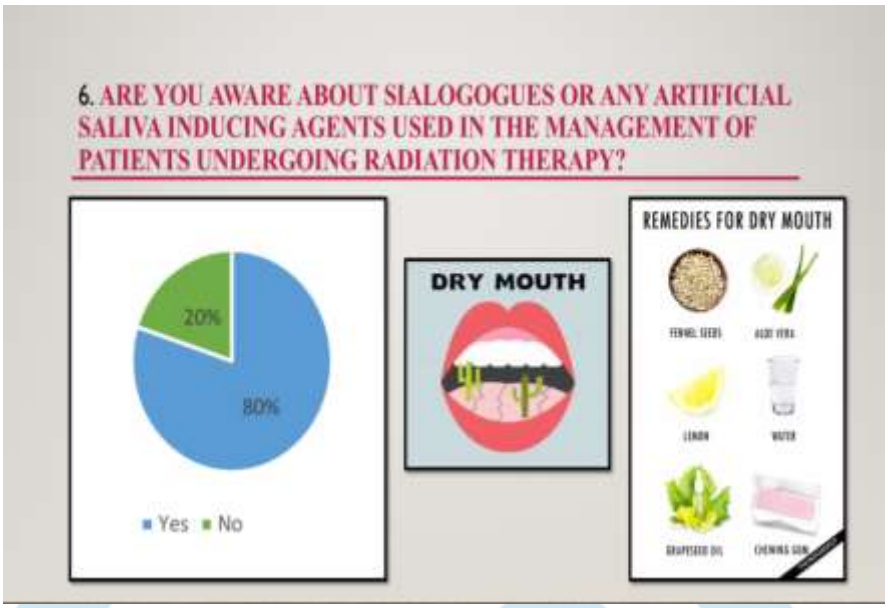
6. ARE YOU AWARE ABOUT SIALOGOGUES OR ANY ARTIFICIAL SALIVA INDUCING AGENTS USED IN THE MANAGEMENT OF PATIENTS UNDERGOING RADIATION THERAPY?
20%
80%
Yes
No
DRY MOUTH
REMEDIES FOR DRY MOUTH

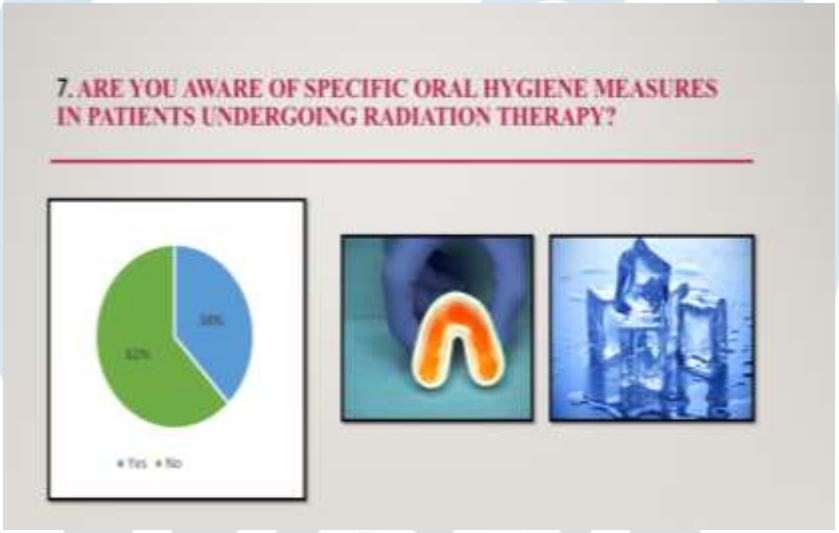
7. ARE YOU AWARE OF SPECIFIC ORAL HYGIENE MEASURES IN PATIENTS UNDERGOING RADIATION THERAPY?

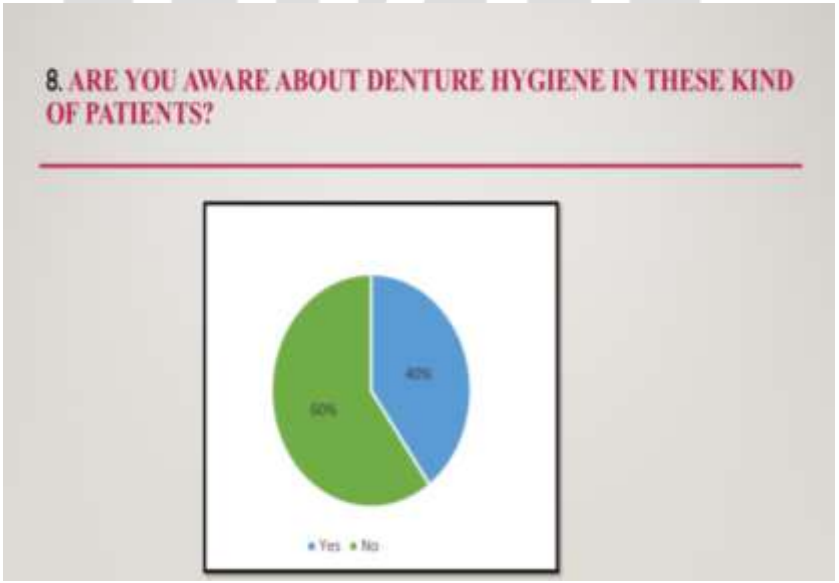
8. ARE YOU AWARE ABOUT DENTURE HYGIENE IN THESE KIND OF PATIENTS?
40%
60%
Yes
No

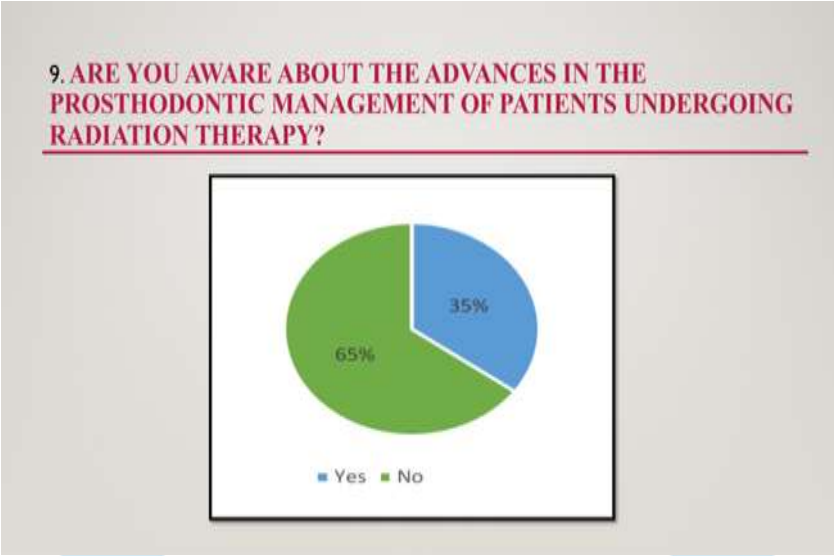

DISCUSSION:

The dentist caring for a head and neck cancer patient should have clearly defined goals of dental management during the three phases of treatment:

1. Pretreatment goals
 a. eliminate potential sources of infection; b. counsel patient about short- and long-term complications of cancer therapy; c. provide preventive care.
 2. Goals during cancer therapy
 a. provide supportive care for oral mucositis; b. provide treatment of oral candidiasis; c. manage xerostomia; d. prevent trismus.
3. Long-term, post-treatment goals
 a. manage xerostomia; b. prevent and minimize trismus; c. prevent and treat dental caries; d. prevent postradiation osteonecrosis (ORN); e. detect tumor recurrence.

Role of a prosthodontist as a member of the multidisciplinary team :

Patients who have had surgery will often require prosthodontic rehabilitation to improve the mastication, speech, swallowing and to improve their QOL and reintegrate into society. Prosthodontic rehabilitation of such patients is rather challenging and requires coordinated integration within a multidisciplinary team.[8-10] Members of the team often include an oral-maxillofacial surgeon, radiologist, oncologist, neurosurgeon, otolaryngologist, prosthodontist, speech therapist and social worker amongst others to treat the individual patients' physical, social-psychological and spiritual problems. As a critical member of the team, the maxillofacial prosthodontist coordinates the efforts in many facets of the patient's rehabilitation care. The prosthodontist is involved in diagnostic examination, restoration, maintenance of oral functions, comfort, esthetics and health of patients who are undergoing surgery, chemotherapy and/or radiotherapy for head and neck cancer. Care should be patient-centered and patient-directed.

According to the survey , when the students where questioned about the prosthodontic treatment planning for radiotherapy patients , only 38% were aware and 62% were unaware .

As mentioned above pre treatment management should be done along with some pre cautions when placing implants or when doing any surgical procedures among radiotherapy patients. The precautions might be antibiotic prophylaxis, hyperbaric oxygen therapy , tooth mousse.

Hyperbaric oxygen (HBO) treatment has been used to improve or cure disorders involving hypoxia and ischemia, by enhancing the amount of dissolved oxygen in the plasma and thereby increasing O2 delivery to the tissue. HBO treatment enhances the amount of dissolved oxygen in the plasma, thereby increasing O2 tissue delivery independent of hemoglobin [11]. As in normal tissue, the pO2 in cancer tissue increases significantly during HBO exposure [12]. Thus, elevation of the tumor oxygen pressure has been shown to be preserved clinically for approximately 30 min after HBO exposure [13,14].

Radiotherapy and mouth:

90% of the participants were aware about the effect of radiation therapy on teeth but they were not aware about the treatment done to reduce the effects.

Radiotherapy can affect white blood cells, skin cells and the lining of your mouth. Dry mouth, mucositis , loss of taste are few radiotherapy effects.

Dry mouth: saliva lubricates mouth and assists speech. A decrease in salivary flow will interfere with denture retention since the saliva contributes to adhesion, cohesion, interfacial surface tension and capillarity.Difficulty in mastication and deglutition. The denture use should be limited to short periods. Restrict the diet to nutritious moist food that are soft or liquid. Sialalogues , soft liners and tissue conditioners can be used . Silicone liners have been suggested in order to reduce the injury to the tissues. But , they causes reduction of wettability of tissues which leads to increased drag, as the slidding of denture

easily over the mucosa is not accomplished properly. There is a more rapid degradation of the silicone liners because of increased fungal population due to xerostomia. Silicone liners have thus been proven to be less effective than acrylic resin in the post radiotherapy denture patient [15].

Mouth ulceration: Ulcertaion and inflammation of the lining of the mouth occurs in areas of that are directly affected by radiation. Tissues become red, swollen and painful ulcers may develop. Varying dentures may be uncomfortable. Ulcers usually heal after treatment has finished. Mouth washes and gels may help to reduce your discomfort.

Loss of taste: Radiation can affect your taste buds. You may experience loss of taste. Radiation treatment applied to head and neck are can affect the number of taste buds remaining at the completion of treatment. Using chlorohexidine mouth wash is recommended during oncology treatment. Mouth wash can change the surface of the tongue and alter taste. Taste often recovers once cancer treatment is complete.

Osteoradionecrosis: This is a severe complication that can occur following radiotherapy and affects the bones ability to heal. Tooth extraction following radiotherapy can make the condition worse. For this reason, dental work should be completed before starting radiotherapy.

Prosthodontic treatment planning:
Among 100 participants only 38% were aware about the prosthodontic treatment planning.
As a preventive measure, radiotherapy protective devices/stents can be fabricated and used during the treatment. These devices are used to displace the position or to shield tissues or to assist in the efficient administration of radiotherapy to the affected areas, thus limiting the post therapy morbidity [16,17,18]. The prosthodontist can actively help in the rehabilitation of cancer patients by fabricating a whole array of possible prostheses that can be constructed to meet specific patient needs, thereby limiting complications following therapy. Perioral Cone Positioning Stents, Position Maintaining Stents, Tongue Depressing Stents, Tissue Recontouring Stents, Tissue Bolus Compensators/ Balloon Bolus Supporting Stents are the various stents constructed by a prosthodontist. Complete denture with definitive obturator can be given. Denture care is must in these kind of patients. So when the participants were asked about denture care only 40% were and 60% were unaware.

Denture care:
- Rinse your dentures after meals.
- Brush dentures daily with soft brush and mild soap.
- Don't use tooth paste - it's abrasive and may cause wear to denture.
- Place your dentures in cold water at night and when they are not in your mouth.
- If your dentures are stained, a small amount of vinegar or bleach may be added to the water .
- Rinse with water before wearing.
- Denture should fit well to maintain a healthy mouth.
- It may help to add a small amount of denture adhesive to the fitting surface of the denture .
- Lubricants , such as KY Jelly , can also be used because patients may have xerostomia If dentures sores or ulcer develop denture should not be worn until adjusted by a dentist or until the sores have healed

Guide plane prosthesis, Palatal oburators are also constructed . Especially when it is likely that postoperative radiotherapy is indicated, some authors advice to insert implants immediately following the ablative procedure in the same session [19,20,21,22,23]. The major advantages of implant placement during ablative surgery reported in literature include: • Initial implant healing (osseointegration) takes place before irradiation; • Implant-surgery in a due to radiotherapy compromised area is avoided thus reducing the risk of late complications, such as development of osteoradionecrosis; • The patient can benefit from the support of the implants in an earlier stage after treatment. Among others this support is important for the rehabilitation of speech and swallowing; • The patient is saved from another surgical intervention; • There is no need for adjunctive HBO therapy. [20,24,25].

CONCLUSION:
Overall , awareness about prosthodontic treatment planning in patients undergoing radiation therapy is poor among dental students. Therefore, communication and education should be improved for dental students about prosthodontic treatment planning on patients undergoing radiation therapy through various educational programmes , workshops and conferences.
Relevant research on biomaterials, including osseointegrated implants, microvascular free flap tissue transfers, bone grafting, hyperbaric oxygen therapy, technological advances in imaging modalities, and use of implants[26] have collectively enhanced rehabilitation outcomes. Technological innovations like CADCAM are revolutionalizing the field. With Rapid Prototyping, a life-like prosthesis of the defect can be fabricated.[27,28] Software allows virtual designing of prostheses enhancing the outcome and thus improving the quality of life. Development in the field of tissue engineering has resulted in the formation of new tissue equivalents of bone and cartilage that will augment the outcome of prosthodontic rehabilitation in future.[29,30].

REFERENCE:
1. Bhide, S.A., Nutting, C.M. Advances in radiotherapy for head and neck cancer. Oral Oncol 2010; 46 (6): 439-441.
2. Brizel, D.M., Wasserman, T.H., Henke, M., et al. Phase III randomised trial of amifostine as a radioprotector in head and neck cancer. J Clin Oncol 2000; 18 (19): 3339-3345.

3. Dreizen S. Oral complications of cancer therapies. Description and incidence of oral complications. NCI Monogr 1990:11-5.
4. Kahnz Z, Farman AG. Th e prosthodontic role in head and neck cancer and introduction oncology dentistry. J Indian Prosthodont Soc 2006;6:4-9.
5. Ztolow IM. Dental oncology and maxillofacial prosthetics. In: Shah JP, Patels SG, editors. Cancer of Head and Neck. 1st ed. USA: PMPH; 2001. p. 376.
6. Dirix P, Nuyts S, Van den Bogaert W (2006) Radiation-induced xerostomia in patients with head and neck cancer: a literature review. Cancer 107:2525–2534.
7. Bruno C. Jham &Patricia M. Reis & Erika L. Miranda & Renata C. Lopes & Andre L. Carvalho & Mark A. Scheper & Addah R. Freire .Oral health status of 207 head and neck cancer patients before, during and after radiotherapy , ClinOralInvest(2008)12:19–24.
8. Davenport J. Managing the Prosthetic Rehabilitation of patients with Head and Neck Cancer. Dental News 1996;3:7-11.
9. Armbruster PC, Grossman Y, Shannon M, Finger IM, Walters P. A multidisciplinary approach to restoring an acquired palatal defect using distraction osteogenesis: A clinical report. J Prosthet Dent 2004;92:316-21.
10. Hubalkowa H, Holakovsky J, Bradza F, Diblik P, Mazanek J. Team approach in the treatment of extensive Maxillofacial defects- Five case Report series. Prague Med Rep 2010;3:148-57.
11. Gill AL, Bell CNA. Hyperbaric oxygen: its uses, mechanisms of action and outcomes. QJM. 2004;97:385–395.
12. Brizel DM, Lin S, Johnson JL, Brooks J, Dewhirst MW, Piantadosi CA. The mechanisms by which hyperbaric oxygen and carbogen improve tumor oxygenation. Br J Cancer. 1995;72:1120–1124.
13. Kinoshita Y, Kohshi K, Kunugita N, Tosaki T, Yokota A. Preservation of tumor oxygen after hyperbaric oxygenation monitored by magnetic resonance imaging. Br J Cancer. 2000;82:88–92. doi: 10.1054/bjoc.1999.0882.
14. Beppu T, Kamada K, Yoshida Y, Arai H, Ogasawara K, Ogawa A. Change of oxygen pressure in glioblastoma tissue under various conditions. J Neurooncol. 2002;58:47–52.
15. Shweta Prakash, Meenakshy Hari, Gautam Shetty ,Ramesh chowdhary Prosthodontic Rehabilitation and Management of Irradiated Edentulous Patients - A Review . Journal Of Applied Dental and Medical Sciences 2(1);2016 .
16. Kaanders JH, Fleming TJ, Ang KK, Maor MH, Peters LJ. Devices valuable in head and neck radiotherapy. Into J Riadial Once Boil Phys 1992; 23 (3): 639-45.
17. Chambers MS, Tooth BB, Fleming TJ, Lemon JC. Oral and Dental Management of the cancer patient: prevention and treatment of complications. Support Care Cancer 1995; 3:168-75.
18. Sheaf NG. Maxillofacial prosthetics and head and neck cancer patients. Cancer 1984; 54:2682-90.
19. Kwakman JM, Freihofer HP, van Waas MA. Osseointegrated oral implants in head and neck cancer patients. Laryngoscope 1997;107(4):519–22.
20. Sclaroff A, Haughey B, Gay WD, Paniello R. Immediate mandibular reconstruction and placement of dental implants. At the time of ablative surgery. Oral Surg Oral Med Oral Pathol 1994;78(6):711–77.
21. Marx RE, Morales MJ. The use of implants in reconstruction of oral cancer patients. Dent Clin North Am 1998;42(1): 177–202.
22. Mericske-Stern R, Perren R, Raveh J. Life table analysis and clinical evaluation of oral implants supporting prostheses after resection of malignant tumors. Int J Oral Maxillofac Implants 1999;14(5):673–80.
23. Urken ML, Buchbinder D, Weinberg H, Vickery C, Sheiner A, Biller HF. Primary placement of osseointegrated implants in microvascular mandibular reconstruction. Otolaryngol Head Neck Surg 1989;101(1):56–73.
24. Wei FC, Santamaria E, Chang YM, Chen HC. Mandibular reconstruction with fibular osteoseptocutaneous free flap and simultaneous placement of osseointegrated dental implants. J Craniofac Surg 1997;8(6):512–21.
25. Urken ML, Buchbinder D, et al. Functional evaluation following microvascular oromandibular reconstruction of the oral cancer patient: a comparative study of reconstructed and nonreconstructed patients. Laryngoscope 1991;101(9):935–50.
26. Roumanas ED, Chang TL, Beumer J. Use of Osseointegrated Implants in the Restoration of Head and Neck Defects. J Calif Dent Assoc 2006;34:711-8. 33.
27. Sykes LM, Parott AM, Owen CP, Snaddon DR. Applications of Rapid Prototyping techniques in Maxillofacial Prosthesis. Int J Prosthodont 2004;17:454-9. 34.
28. Davis BK. The role of technology in facial Prosthetics. Curr Opin Otolaryngol Head Neck Surg 2010;18:332-40. 35.
29. Bailey BJ, Johnson JT, Newlands SD. Surgical Techniques to Enhance Prosthetic Rehabilitation. In: Head and Neck Surgery-Otolaryngology. 4th ed. Philadelphia: Lippincott Williams and Wilkins; 2000. p. 1864.
30. Baun BJ, Mooney DJ. The impact of tissue engineering on Dentistry. J Am Dent Assoc 2000;131:309-18.