DIMENSIONAL VARIATION IN ATLAS VERTEBRAE IN SOUTH INDIANS

Running title: Atlas bone in south indians
Type of article: Original research

M. Leo Bernard Manuel
Graduate,
Saveetha dental college.
Saveetha Institute of Medical and Technical Sciences.
Saveetha University.

Dr. Saravanan,
Department of anatomy,
Saveetha dental college
Saveetha Institute of Medical and Technical Sciences.
Saveetha University.

Corresponding author
Dr. Saranavan,
Department of anatomy,
Saveetha dental college
Saveetha Institute of Medical and Technical Sciences.
Saveetha university.
Poonamalle high road,
Velapanchavadi
Chennai-77

ABSTRACT

Aim:
To quantitatively analyse dry atlas vertebra of South Indians and to record the variation in its measurement.

Objective:
To measure the antero-posterior width of atlas vertebra from dried bone samples of South Indians using Vernier callipers and to statistically analyse the difference in their dimensions.

Background:
The first cervical vertebra, namely the atlas (C1) has different anatomical features from other cervical vertebrae. The atlas holds the globe of the skull and is devoid of body and spine. In this study, thirty five dried specimens of atlas vertebrae were examined. Various dimensions of the vertebra was measured using Vernier calliper and any abnormalities present in it were noted down and photographed. Statistical analysis of the measurements was done. The knowledge of these measurements and the variations present may be of importance to Orthopaedic and Neuro surgeons. This information may also be helpful in avoiding and reducing complications such as vertebral artery injury or spinal cord injury during spine surgeries.

Materials and Methods:
In this study thirty five human C1 vertebrae of unknown age and sex were examined and measurements made. All parameters were measured using a Vernier calliper.

Reason:
This information may also be helpful in avoiding and reducing complications such as vertebral artery injury, spinal cord injury during spine surgeries.

Keywords: atlas, axis, vertebral dimensions, vertebra, foramen.

INTRODUCTION

The first cervical vertebra(C1) has a variable dimension from the other cervical vertebrae. It is one of the important vertebrae as it connects the vertebral column to the occipital bone through foramen magnum. Injuries occurring to this bone can be fatal. Various surgical techniques such as inter-laminar clamp, inter-spinous wiring, plate and screw fixation have been currently employed to correct the instability of the atlanto-axial complex or occipito-cervical junction caused by numerous traumatic and non-traumatic conditions. Recently, transarticular and transpedicular screws fixation have been widely used in stabilizing the cervical column. In

spite of the benefits conferred by transpedicular screw fixation in the cervical column, controversy exists regarding its potential risk.[1] Incorrect insertion of pedicle screws can cause damage to adjacent vital structures such as the spinal cord, nerve roots, cranial nerves, and vertebral arteries. Clinically, iatrogenic injury to the vertebral artery during an approach to the atlanto-axial region is rare but has a potential hazard. There are few reports on the quantitative anatomy of the atlas. This study aims to evaluate the various dimensions of the first vertebrae quantitatively and analyse their relationship with the vertebral artery foramen, in addition to determining the safe sites for different surgical approaches.

METHODS AND MATERIALS

In this study, thirty atlas vertebra(c1) were examined. The C1 vertebra taken for examination was irrespective of age and sex. The C1 vertebrae for the studies were made sure that they were free from osteophytes or metastatic tumours and intact[2]. The thirty atlas vertebrae were measured using a Vernier calliper for an accuracy of 0.01mm in measurement.

RESULT

The mean and range of all measurements done on atlas are shown in the Table 1. In most of the vertebrae, the shape of superior articular facet was oval, then it was figure of eight and then kidney shaped, on a minor scale the shape was bi-lobed, tri-lobed and irregular, in a very few it was triangular, V- shaped and leaf shaped[3].

Table1: Atlas dimensions measurement

S.No	Description of the parameter	Measurement mean value(mm)	
1	Width of Atlas Vertebra	71.56	
2	The Outer distance of vertebral artery foramen	58.35	
3	The Inner distance of vertebral artery foramen	46.01	
4	The Outer distance of vertebral artery groove	Right	22.73
		Left	21.23
5	The Inner distance of vertebral artery groove	Right	12.89
		Left	12.82
6	Length of the superior articular facet	Right	22.05
		Left	21.33
7	Width of Superior Articular Facet	Right	11.11
		Left	10.89
8	The maximum A-P dimension of the vertebral canal	29.94	
9	The maximum transverse dimension of the vertebral canal	27.13	
10	Length of the inferior articular facet	Right	17.90
		Left	17.55
11	Width of the inferior articular facet	Right	13.93
		Left	14.98

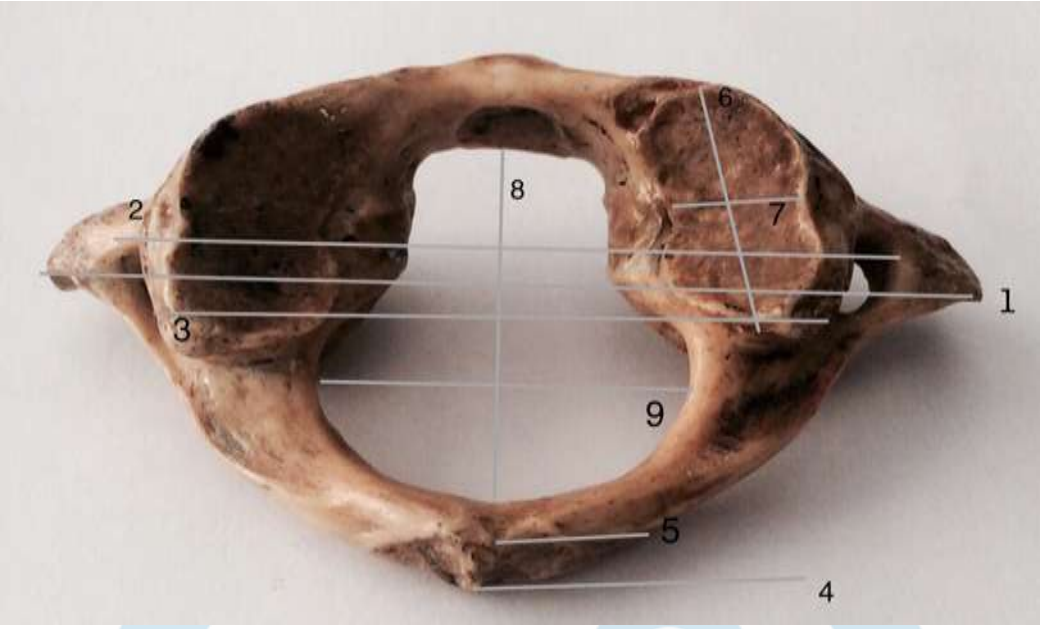

Fig 1: The width of the C1 vertebrae denoted as 1. The outer distance of the vertebral artery foramen is denoted as 2. The inner distance of the vertebral artery foramen denoted as 3. The outer distance of the vertebral artery groove is denoted as 4. The inner distance of the vertebral artery foramen is denoted as 5. The length of the superior articular facet is denoted by 6. The width of the superior articular performance is 7. The antero-posterior dimension of the vertebral canal and the maximum transverse dimension of the vertebral foramen is denoted by 8 and 9.

Fig 2: The length of the inferior articular facet and width of the inferior articular facet is denoted by 10 and 11.

DISCUSSION

Francis in 1952 reported the total anterior and posterior diameter of 285 atlas vertebrae. Liu et al reported detailed external dimensions and facet joint surface morphologies on a total of three C1 vertebrae.[4]

Atlas dimensions of the articular surface of inferior and superior facets: The inferior facet of atlas was circular or water drop-shaped. No significant difference was observed in the mean antero-posterior (A-P) and transverse dimensions on the two sides of the C1 vertebrae. The mean A-P dimension of the articular surface of the superior facet was 22.05 mm, and the mean transverse dimension was 21.33 mm. Inferior facets of C1 always pointed towards the vertebral foramen. No statistical difference was observed in the mean thickness and angles on either side of all C1 vertebrae. The minimum lateral mass dimensions found from 240 Atlas lateral masses were 13.15 mm anterior-posterior, 4.22 mm medial-lateral, and 4.73 mm cephalocaudal. The height of the posterior arch at the groove for the vertebral artery (pedicle analog) was less than 4 mm in 46 of 240 (19.2%) arches.[5]

.

The posterior arch showed the highest number of asymmetries and many unequal grooves for the vertebral artery were observed. The lateral compartment frequently revealed asymmetries of transverse processes and transverse foramina.[6]The superior facet of atlas was oval or kidney-shaped. Oval-shaped superior facets were observed in 69% of atlas vertebrae, and kidney-shaped superior facets were seen in the remaining 31%. No statistical difference was calculated in the data of A-P dimensions of superior articular facet surfaces on both sides of the atlas. The superior articular facets of C1 vertebrae were not as symmetric as the other side. The

mean A-P dimension was 21.69mm. Superior articular facets of C1 also pointed towards the vertebral foramen as well as the inferior facets. The anterior point of the superior facets was nearer to the midline than their posterior point. The mean transverse dimension of the articular surface of the superior facet of C1 was 11.01 mm, which was longer than the mean A-P dimension. The distance between both tips of the transverse processes of the atlas ranged from 29.31 to 83.98mm (mean 71.56 mm). The transverse foramen was found to be in the transverse process lateral to the lateral mass in all C1 vertebrae[6]. The mean distance between both innermost edges of the transverse foramen was 46.01 mm (43.95-60.03mm). The mean distance between both outermost edges of the transverse foramen was 58.35mm (50.76-70.01mm). The mean maximum A-P dimension of the vertebral canal was 29.94 mm , the mean maximum transverse dimension of the vertebral canal was 27.13.The meandistance from midline to the innermost edge of the vertebral artery groove was 12.85 mm);the mean distance from the midline to the outer edge of the vertebral artery groove on outer cortex was 21.98 mm. No significant difference was observed between the data of two sides. The classically described kidney-shaped facet was in fact an infrequent finding. Upon comparison of right and left sides, none (0%) of the facets were mirror images of symmetry, while 19 of the atlases (63%) had grossly asymmetrical facets, and 11 of 30 atlases (37%) had facets which were only slightly asymmetrical in regard to shape, border, depth and angle.[8]

As surgical techniques and instrumentation for treatment of unstable cervical spine as a result of traumatic, congenital or neoplastic disorders continue to evolve, more knowledge about bones and surrounding anatomy is required. The relationship between the vertebral artery and C1-C2 vertebrae has a determining role in planning an operative approach. Various techniques such as inter-laminar clamp and hook plating, lateral screw and plate fixation, and inter-spinous wiring have been described for treating cervical instability[9]. The measurements done in this study may be helpful in avoiding and reducing complications such as vertebral artery injury, spinal cord injury, and cranial nerve damage during a C1 stabilizing operation[10].

REFERENCES

[1] **GUPTA, C.1*, RADHAKRISHNAN, P.1, PALIMAR, V.2, D'SOUZA, AS.1 and KIRUBA NL**. A quantitative analysis of atlas vertebrae and its abnormalities.

[2] **SENGÜL, G. and KADIOGLU, HH**. Morphometric Anatomy of the Atlas and Axis Vertebrae. Turkish Neurosurgery, 2006, vol. 16, n. 2, p. 69-76.

[3] **EBRAHEIM NA, XU R, LIN D, AHMAD M, HECK BE.** The quantitative anatomy of the vertebral artery groove of the atlas and its relation to the posterior atlantoaxial approach. Spine 23: 320-323, 1998

[4] The Quantitative Anatomy of the Atlas. Doherty, Brian J. PhD; Heggeness, Michael H. MD, PhD

[5] C1 Anatomy and Dimensions Relative to Lateral Mass Screw Placement
Christensen, David M. MD*; Eastlack, Robert K. MD†; Lynch, James J. FRCSI‡; Yaszemski, Michael J. MD, PhD*; Currier, Bradford L. MD*

[6] **Sisira padavala** 1st yr BDS, Saveetha Dental College and Hospitals, Saveetha University, Chennai. Study of Foramen Vesalius and its Clinical Implications.

Research Journal of Pharmacy and Technolog Year : 2015, Volume : 8, Issue : 8 First page : **(1127)** Last page : **(1128)**

[7] Left-right asymmetries and other common anatomical variants of the first cervical vertebra: Part 1: Left-right asymmetries in C1 vertebrae. l.Van RoyD.CaboorS.De BoelpaepE.BarbaixJ.P.Clarys

[8] **GUPTA S, GOEL A.** Quantitative anatomy of the lateral masses of the atlas and axis vertebrae. Neurol India 48 :120-125, 2000

[9] Gottlieb MS: Absence of symmetry in superior articular facets on the first cervical vertebrae in humans. J Manipulative Physiol Ther 1994;17:314-20.

[10] **KARAU, BP., OGENG'O, JA., HASSANALI, J. and ODULA, PO.** Morphometry and Variations of Bony Ponticles of the Atlas Vertebrae (C1) in Kenyans. International Journal of Morphology, 2010, vol. 28, n. 4, p. 1019-1024.